



DIAGNOSTIC CHALLENGE

Check the correct answer on page 75

Case 1

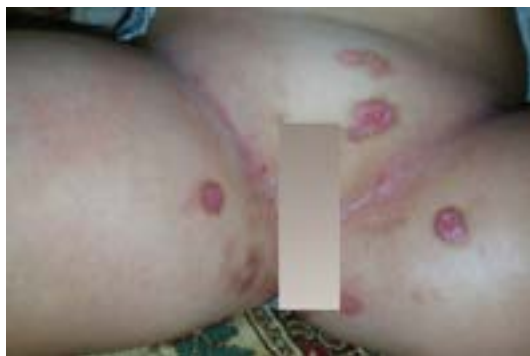

Figure 1a

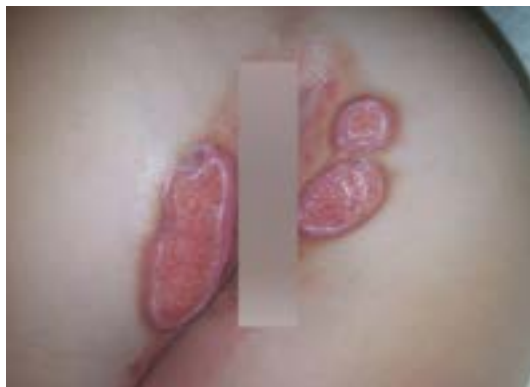

Figure 1b

An otherwise healthy, 8-week-old baby girl was seen for a rash, that presented as redness and ulcerations in the diaper area. Over-the-counter creams, Bacitracin, Nystatin, Hydrocortisone, Zinc Oxide, and Benzalkonium Chloride had been used by the parents but were ineffective. Examination revealed symmetrical, well-demarcated erythematous macular diaper rash on which multiple, well demarcated ulcers with central granulation and raised borders were present, both anteriorly (Figure-1a) and posteriorly in the perianal area (Figure-1b). There was no rash on any other part of the body.

1. What is your diagnosis of this case?
2. What other important things you will consider in differential diagnosis?

Case 2

*Courtesy Dr. Moizza Tahir
Combined Military Hospital, Rawalpindi*

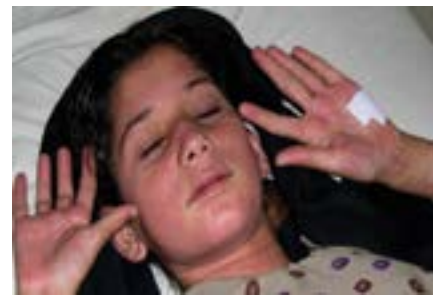

Figure 1

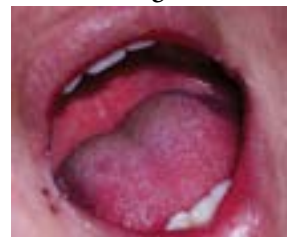

Figure 2

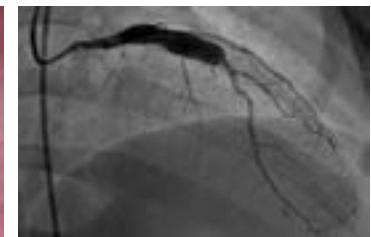


Figure 3a

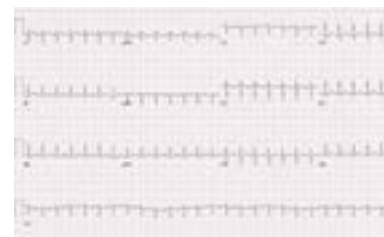

Figure 3b

A 5-year-old female child presented to dermatology clinic for evaluation of a rash along with fever of six days. The rash was maculopapular in nature, present over her face, trunk and limbs with swelling and skin-peeling over the hands (Figure 1). Oral mucosae and tongue were also involved (Figure 2). She was febrile with temperature of 99.9 °F and heart rate of 102 per minute. Lymph nodes were enlarged in the cervical region. Investigations revealed an ESR of 80 mm fall at the end of first hour, TLC 12x10⁹ per ml and platelets 700x10⁹ per mm. Cardiac investigations are shown in Figure 3 a & b.

1. What is your diagnosis?
2. How will you manage this case?